

CLINICAL REPORT

The facial flow concept: An organic orofacial analysis—the vertical component



Bruno Pereira Silva, DDS, PhD,^a Eduardo Mahn, DDS, PhD,^b Kyle Stanley, DDS,^c and Christian Coachman, DDS, CDT^d

Dental care includes not only treating oral health but also improving the appearance of the patient's smile. The smile is probably the most remarkable and contagious social expression experienced by humans and has a considerable impact on facial beauty.^{1,2} Facial symmetry has even been suggested as important in choosing partners.³ A positive relationship between facial symmetry and beauty has been reported,^{1,4} and smile symmetry has been applied in esthetic dentistry and has been assumed as an esthetic goal.^{1,3,4}

The purpose of this clinical report was to present the concept of facial flow (FF). The FF concept is divided into 2 components; vertical and horizontal. The vertical component guides the evaluation of the relationships among the facial midline (FM), dental midline (DM), and tooth axis to understand the DM shift and tooth axis cant with the face and help determine a better position for both in designing new smiles. The horizontal component guides evaluation of the relationships among facial anatomic features that create horizontal lines such as the interpupillary line, the commissural line, the mandibular angle, and the ramus and their relationships to the occlusal plane and incisal edges of the maxillary teeth.

The importance of symmetry among facial structures increases with proximity to the midline.⁵ The first step in a facially driven smile design is determining the

ABSTRACT

Orofacial analysis has been used by dentists for many years. The process involves applying mathematical rules, geometric principles, and straight lines to create either parallel or perpendicular references based on the true horizon and/or natural head position. These reference lines guide treatment planning and smile design for restorative treatments to achieve harmony between the new smile and the face. The goal is to obtain harmony and not symmetry. Faces are asymmetrical entities and because of that cannot be analyzed using purely straight lines. In this article, a more natural, organic, and dynamic process of evaluation is presented to minimize errors and generate harmoniously balanced smiles instead of perfect, mathematical smiles. (*J Prosthet Dent* 2019;121:189-94)

horizontal and vertical position of the maxillary central incisors. The horizontal position of the FM is an important reference line for both restorative dentists and orthodontists.¹ Authors have discussed which facial landmarks are best to define the FM and consequently the DM.⁶⁻⁸

The relative position of the DM according to the FM has been controversial,⁹⁻¹³ although most agree that having the DM coincident with the FM transmits a sense of symmetry, balance, and harmony.⁹⁻¹³ It is also true that a certain tolerance of discrepancy is acceptable.^{12,14-18}

Bidra and Cols⁶ stated that “the hierarchy of anatomic landmarks closest to the midline of the face in the smile was as follows: the midline of the oral commissures, natural dental midline, tip of philtrum, nasion, and tip of the nose.” They defined the FM as a line bisecting the distance between exocanthions. However, Owens et al,⁷ in a multicenter study, defined the FM as the line bisecting the interpupillary distance and found that 70% of all participants had a DM coincident with the FM. Miller and Jamison⁸ published the first paper on this

^aClinical Professor, Department of Periodontology of School of Dentistry, University of Seville, Seville, Spain.

^bDirector, Esthetic Dentistry Program, Department of Prosthodontics, Faculty of Dentistry, Universidad de los Andes, Santiago, Chile.

^cAdjunct Faculty, Division of Restorative Sciences, Hermann Ostrow School of Dentistry of University of Southern California, Los Angeles, Calif.

^dPrivate practice, Sao Paulo, Brazil.

topic in 1979. They considered the philtrum the most reliable landmark for defining FM and concluded that 70.4% of participants have a DM coincident with FM.

In orthodontic or restorative treatments, clinicians should diagnose the DM position in the facial context for each patient. Depending on which FM definition is chosen, that of Bidra and Cols,⁶ Owen et al,⁷ or Miller and Jamison,⁸ different diagnoses and treatment plans can be considered (Fig. 1), showing just how subjective some of these clinical decisions can be.

Because the human face has an irregular shape, it is impossible to define a midline. This explains why the American Association of Orthodontists and the Glossary of Terms for the American Academy of Facial Plastic and Reconstructive Surgery have no definitions for FM.¹⁹⁻²¹ All human faces are asymmetrical, and no objective scientific criteria is available for distinguishing normal from abnormal asymmetry.¹³

The definition of the FM is controversial. The most important factor may not be finding the exact points that define the midline of a geometrically irregular face but understanding the checks and balances,⁹ something skilled dentists and technicians do intuitively. The purpose of this article was to generate new concepts and guidelines for comprehensive and organic facial analysis so that clinicians may depend less on artistic skills.

CLINICAL REPORT

A 44-year-old woman presented to Silvestre Ripoll Clinic, Seville, Spain, for an esthetic consultation. Her dental status, periodontal status, and occlusal relationship were evaluated. Impressions and photographic and video documentation were then obtained for orofacial analysis and treatment planning purposes (Fig. 1). Reference lines were defined by points or structures considered during the perception process to determine whether the esthetic composition was harmonically distributed. The reference lines of dental or dentofacial compositions are key to biological and structural beauty.^{9,22}

The most important reference lines in the frontal plane are the interpupillary line and the hypothetical FM. These 2 lines define a "T" which functions as the foundation of the facial architecture (Fig. 1A, B).^{9,22} All facial structures have a position relative to these lines, and conventionally, an attractive face also needs the interpupillary line to be parallel to other reference lines: the commissural, base of the nose, and eyebrow lines.^{22,23}

In the authors' opinion, the facial "T" does not need to be perpendicular to the face to make for an attractive and harmonious appearance. The authors find the idea of defining a specific horizontal line and a perpendicular line as the midline for developing a beautiful smile both unnecessary and unrealistic. Facial lines and anatomic

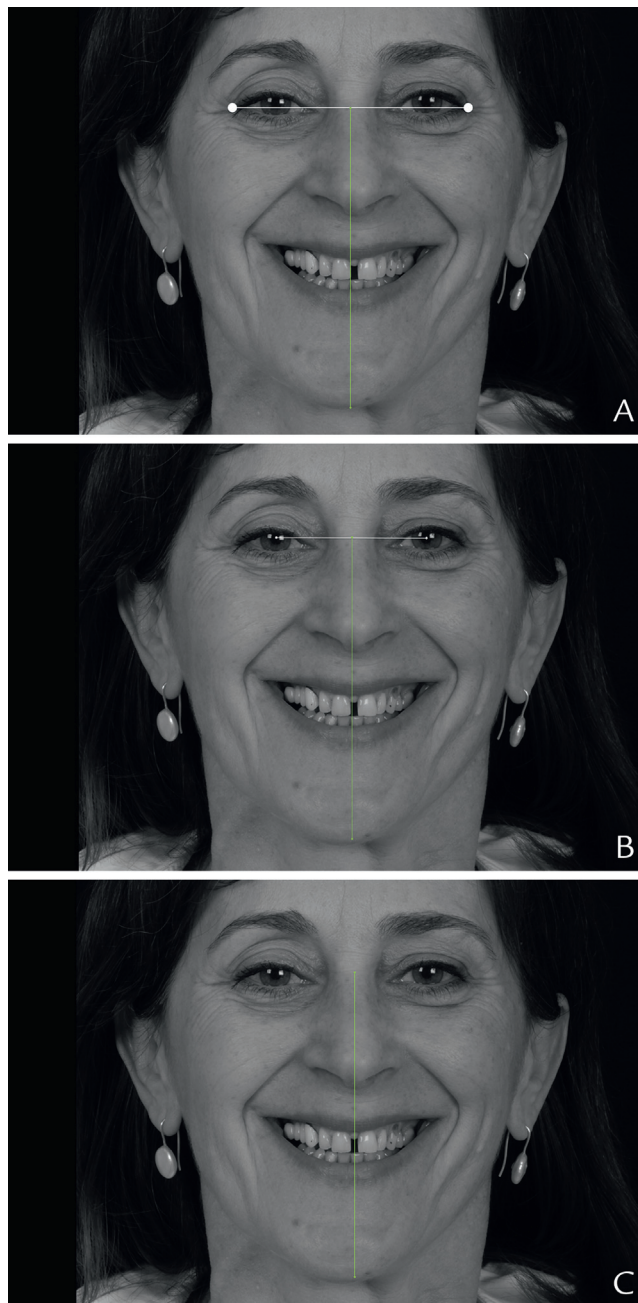

Figure 1. Facial midlines determined by different parameters. A, Line bisecting distance between exocanthions. Note midline not centered on nose or lip. B, Facial midline-determined line bisecting interpupillary distance. These two lines define facial "T." C, Facial midline determined by perpendicular line to horizontal that crosses philtrum.

components do not all need to be strictly parallel to look esthetically pleasing but only to create overall visual comfort.

When a new structure is added to a picture (a new smile in a face), some basic principles can help in the process. Although no mathematical rule can guide clinicians as to how to exactly design the smile in a face,

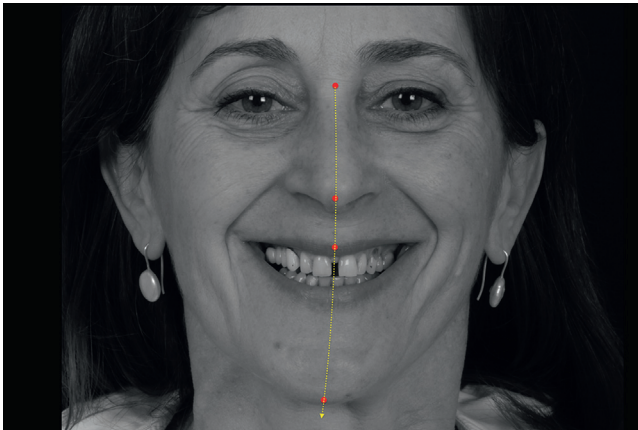


Figure 2. Facial flow determined by orientation of glabella, nose bridge, philtrum, and chin.

they should have a subjective sense of what is visually pleasing. As Cardash et al¹³ said, “the artistic judgment of the individual clinician therefore must be used.” This, according to Langlois et al,²⁴ is an inherent characteristic of human beings. Adults and children agree who is and is not attractive, both within and across ethnicity and cultures, contrary to the common assumption that beauty is in the eye of the beholder.²⁴

In human perception, a line does not really have to be expressed or drawn to be perceived; it can be suggested by 2 or 3 points in a directional movement.^{9,25} In the authors’ opinion, the same thing happens with facial structures located in the center of the face. When a person smiles, a line can be drawn connecting the glabella, nose bridge, philtrum, and chin which is not always straight. The authors refer to this line as the “facial flow line” (FFL) (Fig. 2) and consider it the foundation of the entire facial architecture. The authors believe that all facial structures have a position relative to this line, which is responsible for a sense of harmony and balance.

Discrepancies must be evaluated to avoid under- or overtreatment. Thus, the new vertical reference for facially driven esthetic treatment should be the FFL. All FF structures, glabella, nose bridge, philtrum, and chin, are located in the center of the face and define a large line of force, which has an important effect on facial balance. The authors believe that by connecting the dots between these landmarks, starting from the natural head position, clinicians can define the FF of their patients to better understand the disposition and organization of facial structures and to plan in a more predictable, esthetic, and functional way.^{26,27} The authors have observed that most faces present an asymmetrical pattern, where facial structures such as nose and chin usually point to the same side (Fig. 2). If clinicians are changing somebody’s smile and are not planning to make facial transformations (plastic surgery or orthognathic or orthopedic



Figure 3. Facial flow directional movement points to right or “green” side.

procedures that affect facial forms) the best possible harmony is achieved by the expression “go with the flow.” If facial transformations are planned, then the clinicians need to integrate the smile design with the facial procedures.

The direction that the FF follows should be understood; that is, the directional movement in which the facial structures travel. The smile and teeth are not exceptions in this flow. FFL usually points to the patient’s left or right side, the side of the face where FFL points have been named by the authors the green side and the opposite the red side. In the case study shown in this article, the face flows to the patient’s right side, meaning the right side of the face was the green side (Fig. 3). In other patients, FFL can also be straight (Fig. 4), which means a neutral flow; in that situation, there is no green or red side. The other option is when the FF is disruptive, meaning that some structures go to one side and others to the other in a similar manner. In such patients, the FF, is also considered neutral. Clinically this means if a small midline shift or inclination falls into the green side (the side that follows the FF), it will be less perceptible and create less visual tension because it will blend with the other facial structures, organization, and parallel relationships.¹²

Because the patient was seeking esthetic treatment, a diagnostic waxing was created from the maxillary right first molar to the maxillary left first premolar and scanned for digital facial integration by using software (NemoSmile Design 3D; Nemotec). This allowed better visualization and the opportunity to make digital adjustments according to the FF before the trial restorations. In this patient, the first diagnostic waxing blended in completely with the facial architecture, and the smile design was kept with the DM slightly inclined toward the green side (Fig. 5) and replicated with the trial restorations (Fig. 6). Once the trial restorations had been approved by the clinician and the patient, without any




Figure 4. Straight facial flow absent of red or green side.

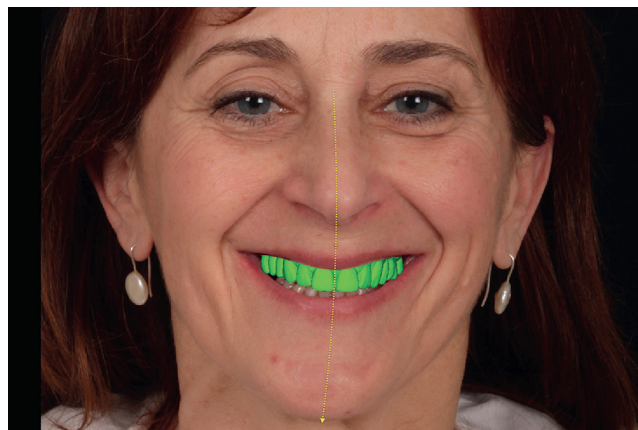

Figure 5. Digital waxing simulated face according to facial flow.



Figure 6. Trial restorations to evaluate smile design and dental midline orientation following facial flow rather than facial midline.



Figure 7. Definitive restorations respecting facial flow.

changes from the initial diagnostic waxing, the teeth were minimally prepared, and ceramic veneers (from the maxillary right lateral incisor to the maxillary left first molar) and a ceramic fixed partial prosthesis (from the maxillary right canine to the maxillary right first molar) were bonded (Fig. 7).

When the DM cant points to the opposite direction of the FFL (Fig. 8), it falls into the red side and can create some visual tension and discomfort. In this patient (Fig. 8), in addition to the angulation of the DM, the tip angulation of the central incisors and the right lateral incisor also pointed to the red side, creating considerable visual tension. Thus, this patient from the FF point of view was a good candidate for orthodontic treatment to correct the DM angulation and the angulation of the lateral incisor, avoiding the direction of the red side.

The authors suggest that photographs and videos be analyzed with the patient using a social smile as this smile is the one most often adopted. However, if patients have a large discrepancy between their social smile and their spontaneous smile, the clinician and patient may

need to evaluate both smile references to make an informed decision. The importance of analyzing the face in motion is emphasized. Movement completely changes perception and what matters in beauty is motion and not a static situation.²⁸ This is why the authors suggest combining the initial FF analysis with 2 or more screenshots from the initial video.

Sometimes the nose and chin can go in opposite directions, describing a curved, “banana”-shaped FFL (Fig. 9). With these patients, the position of the FFL between the lip frame must be noted. This area of the FF curve will allow clinicians to determine which is the green and which is the red side. These situations were also described by Saavedra et al³³ as harmonic facial asymmetry (HFA), dividing patients into 2 types: HFA-positive, if the angulation of the DM followed the curve direction, or HFA-negative, if the angulation of the DM was pointing in the opposite direction. FF is a much broader concept that goes beyond the angulation of the DM relationship and looks at the directional movement of central facial structures and their relationships with all smile components.



Figure 8. Dental midline angulation that points to red side.

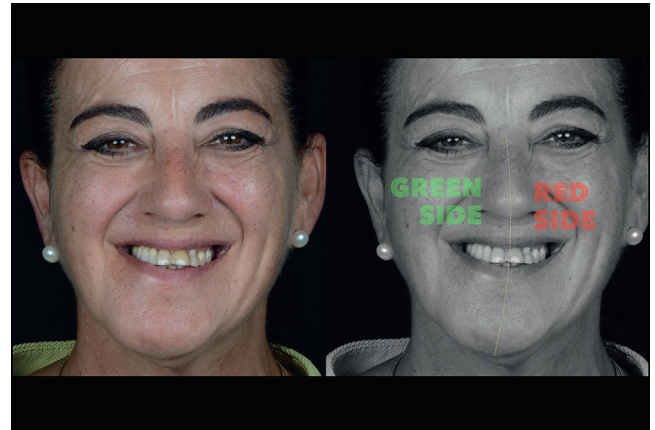

Figure 9. Curved facial flow with “banana” shape. Direction of facial flow in between lip determines green and red side.

DISCUSSION

The final result (Fig. 6) shows how DM orientation was not completely straight, as is often recommended.^{9,16,17,22,25} Also, the DM points to the green side, although the smile fits harmoniously with the rest of the face, conferring a natural appearance to the facial expression.

Corroborating the idea of the FF concept, Silva et al¹² in a study of perceptions concluded that the direction of the DM shift can be a factor in patients who present nose and chin deviations. The threshold of recognition determined for the DM shift was 2 mm when it was following nose and chin deviations but was just 1 mm when it was pointing against nose and chin directions.¹² In a different study regarding DM angulation, the authors concluded that when the direction of the cant follows nose and chin inclinations, it was more esthetically pleasing.²⁹

Facial treatment must consider a large picture, where the eyes, nose, lips, teeth, philtrum, chin, and other facial structures interact. Symmetry has been used in dentistry as a guideline because it is mathematical, predictable, objective, and reproducible. Studies have reported that participants prefer a natural, asymmetrical face to a mirrored, symmetrical face.^{30,31} Other publications reinforce the impact of some facial structures, such as nose and chin, in the perception of smile esthetics.^{11,24}

Gebhard³² referred to the asymmetrical nature of the human face and introduced the “perfect imperfections” concept, meaning that the smile as a facial expression is naturally imperfect but can look harmonious and attractive by blending it with the arrangement of other facial structures. The FF concept introduces a more organic and natural approach to orofacial analysis, respecting the imperfect and asymmetrical nature of the human face.

Aiming for symmetry for so many years has lead clinicians and researchers to try mathematical approaches, using straight lines such as the FM as the main vertical reference line in the diagnostic and smile design process. This approach works in faces that are more symmetrical, although it is unpredictable when even mild asymmetries exist. The concept presented is based on human perception and helps us understand the arrangement of facial structures so that clinicians can better decide whether the final smile design will blend with facial features or incorporate other specialties, which can change the facial frame to improve the final outcome. The precise location of the points and structures suggested to define the FFL should not be a factor, because the aim is to understand the directional movement of the facial structures and define the green and red sides to avoid major mistakes that can compromise treatment.

Research is needed to better define the relationship between the FF and the lips to establish recommendations for an ideal smile design that fits every irregular face.

SUMMARY

Although conventional smile design has often emphasized the use of mathematical analysis of the face, it is not always mandatory to adhere completely to these principles to create an esthetic result. The facial flow concept allows a more organic, intuitive, and perceptual approach respecting the asymmetrical nature of the human face. This new concept redefines facial analysis to make it straightforward and effective for clinicians and laboratory technicians to make facially driven decisions using red and green zones. Just as the vertical reference lines cannot only

be seen as straight lines, the horizontal component of an organic facial analysis is also important and needs further research to relate to the vertical component.

REFERENCES

- Silva BP, Jiménez-Castellanos E, Martínez-de-Fuentes R, Greenberg JR, Chu S. Laypersons' perception of facial and dental asymmetries. *Int J Periodontics Restorative Dent* 2013;33:162-71.
- Ma K, Sellaro R, Lippelt DP, Hommel B. Mood migration: how enfacing a smile makes you happier. *Cognition* 2016;151:52-62.
- Penton-Voak IS, Jones BC, Little AC, Baker S, Tiddeman B, Burt DM, et al. Symmetry, sexual dimorphism in facial proportions and male facial attractiveness. *Proc Biol Sci* 2001;268:1617-23.
- Scheib JE, Ganestad SW, Thornhill R. Facial attractiveness, symmetry and cues of good genes. *Proc Biol Sci* 1999;266:1913-7.
- Springer IN, Wannicke B, Warnke PH, Zernial O, Wiltfang J, Russo PA, et al. Facial attractiveness: visual impact of symmetry increases significantly towards midline. *Ann Plast Surg* 2007;59:156-62.
- Bidra AS, Uribe F, Taylor TD, Agar JR, Rungruanunt P, Neace WP. The relationship of facial anatomic landmarks with midlines of the face and mouth. *J Prosthet Dent* 2009;102:94-103.
- Owens EG, Goodacre CJ, Loh PL, Hanke G, Okamura M, Jo KH, et al. A multicenter interracial study of facial appearance. Part 1: A comparison of extraoral parameters. *Int J Prosthodont* 2002;15:273-82.
- Miller EL, Jamison HC. A study of the relationship of the dental midline to the facial midline. *J Prosthet Dent* 1979;41:657-66.
- Lombardi RE. The principles of visual perception and their clinical application to denture esthetics. *J Prosthet Dent* 1973;29:358-82.
- Zarb GA, Hobkirk J, Eckert S, Jacob R. Prosthodontic treatment for edentulous patients. 13th ed. St. Louis: Mosby/Elsevier; 2012. p. 309-10.
- Latta GH Jr. The midline and its relation to the anatomic landmarks in the edentulous patient. *J Prosthet Dent* 1988;59:681-3.
- Silva BP, Jiménez-Castellanos E, Martínez-de-Fuentes R, Fernández AA, Chu S. Perception of maxillary dental midline shift in asymmetric faces. *Int J Esthet Dent* 2015;10:588-96.
- Cardash HS, Ormanier Z, Laufer BZ. Observable deviation of the facial and anterior tooth midlines. *J Prosthet Dent* 2003;89:282-5.
- Beyer JW, Lindauer SJ. Evaluation of dental midline position. *Semin Orthod* 1998;4:145-52.
- Johnston CD, Burden DJ, Stevenson MR. The influence of dental to facial midline discrepancies on dental attractiveness ratings. *Eur J Orthod* 1999;21:517-22.
- Ker AJ, Chan R, Fields HW, Beck M, Rosenstiel S. Esthetics and smile characteristics from the layperson's perspective: a computer based Surrey study. *J Am Dent Assoc* 2008;139:1318-27.
- Pinho S, Ciriaco C, Faber J, Lenza M. Impact of dental asymmetries on the perception of smile esthetics. *Am J Orthod Dentofacial Orthop* 2007;132:748-53.
- Rodrigues CD, Magnani R, Machado MS, Oliveira OB. The perception of smile attractiveness. *Angle Orthod* 2009;79:634-9.
- American Association of Orthodontists (AAO) glossary 2008. Available at: https://www.aaoinfo.org/system/files/media/documents/AAO%20Glossary_0.pdf. Accessed: July 18th, 2017.
- American Academy of Facial Plastic and Reconstructive Surgery. Glossary of terms. Available at: <http://www.aafprs.org/patient/procedures/glossary.html>. Accessed: July 18th, 2017.
- The Glossary of prosthodontic terms: 9th ed. *J Prosthet Dent* 2017;117(suppl 5):1-105.
- Chiche GJ, Pinault A. Esthetics of anterior fixed prosthodontics. Chicago: Quintessence Publishing; 1994. p. 13-30.
- Arnett GW, Bergman RT. Facial Keys to orthodontic diagnosis and treatment planning. Part I. *Am J Orthod Dentofacial Orthop* 1993;103:299-312.
- Langlois JH, Ritter JM, Roggman LA, Vaughn LS. Facial diversity and infant preferences for attractive faces. *Dev Psychol* 1991;27:79-84.
- Rufenacht C. Fundamental of esthetics. Chicago: Quintessence Publishing; 1990. p. 11-93.
- Weber DW, Fallis DW, Packer MD. Three-dimensional reproducibility of natural head position. *Am J Orthod Dentofacial Orthop* 2013;143:738-44.
- Dong Y, Yin AA, Jia J, Bai SZ. New way to achieve frontal facial photographs of the head in its natural position. *Br J Oral Maxillofac Surg* 2014;52:563-5.
- Coachman C, Calamita MA, Sesma N. Dynamic documentation of the smile and the 2D/3D digital smile design process. *Int J Periodontics Restorative Dent* 2017;37:183-93.
- Silva BP, Jiménez-Castellanos E, Coachman C, Mahn E, Stanley K, Finkel S. Layperson's perception of axial midline angulation in asymmetric faces. *J Esthet Restor Dent* 2018;30:119-25.
- Zaidel DW, Cohen JA. The face, beauty, and symmetry: perceiving asymmetry in beautiful faces. *Int J Neurosci* 2005;115:1165-73.
- Zaidel DW, Deblieck C. Attractiveness of natural faces compared to computer constructed perfectly symmetrical faces. *J Neurosci* 2007;117:423-31.
- Gebhard W. A comprehensive approach for restoring esthetics and function in fixed prosthodontics. In: In Sadan A, editor. Quintessence of dental technology. Hanover Park: Quintessence Publishing; 2003. p. 21-44.
- Saavedra C, García-Adámez R, García-Baeza D, et al. The dental midline angulation—harmonious facial asymmetry concept. Part1 [in Spanish]. *Quintessence* 2015;3:183-18.

Corresponding author:

Dr Bruno Pereira da Silva
 Department of Periodontics
 Faculty of Dentistry
 Calle Avicena 41009, Seville
 SPAIN
 Email: brunopereira.doc@gmail.com

Copyright © 2018 by the Editorial Council for *The Journal of Prosthetic Dentistry*.
<https://doi.org/10.1016/j.prosdent.2018.03.023>