

# Surgically facilitated orthodontic treatment: A systematic review

Elke J. Hoogveen,<sup>a</sup> Johan Jansma,<sup>b</sup> and Yijin Ren<sup>c</sup>  
Groningen, The Netherlands

**Introduction:** Corticotomy and dental distraction have been proposed as effective and safe methods to shorten orthodontic treatment duration in adolescent and adult patients. A systematic review was performed to evaluate the evidence supporting these claims. **Methods:** PubMed, Embase, and Cochrane databases were searched until April 2013 for randomized controlled trials, controlled clinical trials, and case series with 5 or more subjects that focused on velocity of tooth movement, reduction of treatment duration, or complications with various surgical protocols. There were no language restrictions during the search phase. Publications were systematically assessed for eligibility, and 2 observers graded the methodologic quality of the included studies with a predefined scoring system. **Results:** Eighteen articles met the inclusion criteria. Seven studies were clinical trials, with small investigated groups. Only studies of moderate and low values of evidence were found. Surgically facilitated treatment was indicated for various clinical problems. All publications reported temporarily accelerated tooth movement after surgery. No deleterious effects on the periodontium, no vitality loss, and no severe root resorption were found in any studies. However, the level of evidence to support these findings is limited owing to shortcomings in research methodologies and small treated groups. No research concerning long-term stability could be included. **Conclusions:** Evidence based on the currently available studies of low-to-moderate quality showed that surgically facilitated orthodontics seems to be safe for the oral tissues and is characterized by a temporary phase of accelerated tooth movement. This can effectively shorten the duration of orthodontic treatment. However, to date, no prospective studies have compared overall treatment time and treatment outcome with those of a control group. Well-conducted, prospective research is still needed to draw valid conclusions. (*Am J Orthod Dentofacial Orthop* 2014;145:S51-64)

Orthodontic treatment of late adolescent or adult patients can be challenging; often these patients request short treatments.<sup>1,2</sup> If growth modification is no longer possible, surgical procedures might be necessary to attain treatment goals.<sup>3,4</sup> With an osteotomy, both the cortical and trabecular bone is cut, followed by repositioning of the segments by the surgeon. Damage to the nerves and blood supply is a possible complication. For patients with mild dentoskeletal discrepancies, orthognathic surgery might not be a feasible option. To address these issues,

other surgical techniques have been proposed. With a corticotomy, shallow perforations or cuts are made on the cortical alveolar bone only; the trabecular bone is left intact, in contrast to an osteotomy. Orthodontic force is applied shortly after surgery to produce the desired tooth movement and optimal bone remodeling. It has been claimed that orthodontic treatment progresses faster, and that the results were more stable after a corticotomy, with minimal risk of complications.<sup>5</sup> As early as 1959, Köle<sup>5</sup> published various corticotomy and osteotomy designs for different clinical indications. In most cases, he combined interdental corticotomies with a subapical osteotomy.

A common clinical problem is crowding: arch length is typically gained by expansion or proclination of the incisors, and it is potentially unstable and can result in fenestrations. Corticotomy with subsequent bone augmentation has been proposed to increase the volume of the alveolar process, to facilitate arch development, to prevent or even treat fenestrations, and to maximize the metabolic response during orthodontic treatment.<sup>6,7</sup> The invasiveness of these procedures, requiring full mucoperiosteal flaps, might have been a drawback for

From the University Medical Center Groningen, University of Groningen, Groningen, The Netherlands.

<sup>a</sup>Orthodontist, Department of Orthodontics.

<sup>b</sup>Maxillofacial surgeon, Department of Oral and Maxillofacial Surgery.

<sup>c</sup>Professor and orthodontist, Department of Orthodontics.

All authors have completed and submitted the ICMJE Form for Disclosure of Potential Conflicts of Interest, and none were reported.

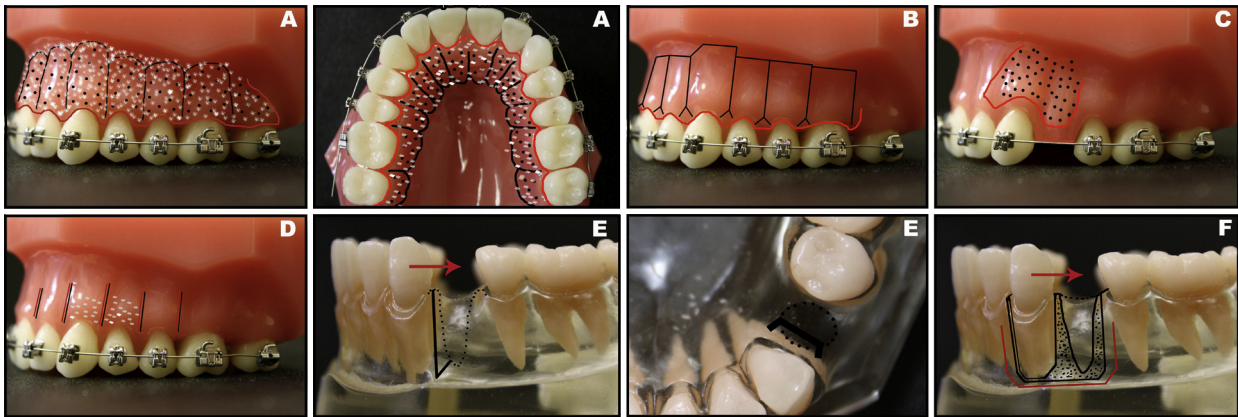
Address correspondence to: Yijin Ren, University Medical Center Groningen, University of Groningen, Department of Orthodontics, Hanzeplein 1, PO Box 30001, 9700 RB Groningen, The Netherlands; e-mail, [y.ren@umcg.nl](mailto:y.ren@umcg.nl).

Submitted, May 2013; revised and accepted, November 2013.

0889-5406/\$36.00

Copyright © 2014 by the American Association of Orthodontists.

<http://dx.doi.org/10.1016/j.ajodo.2013.11.019>



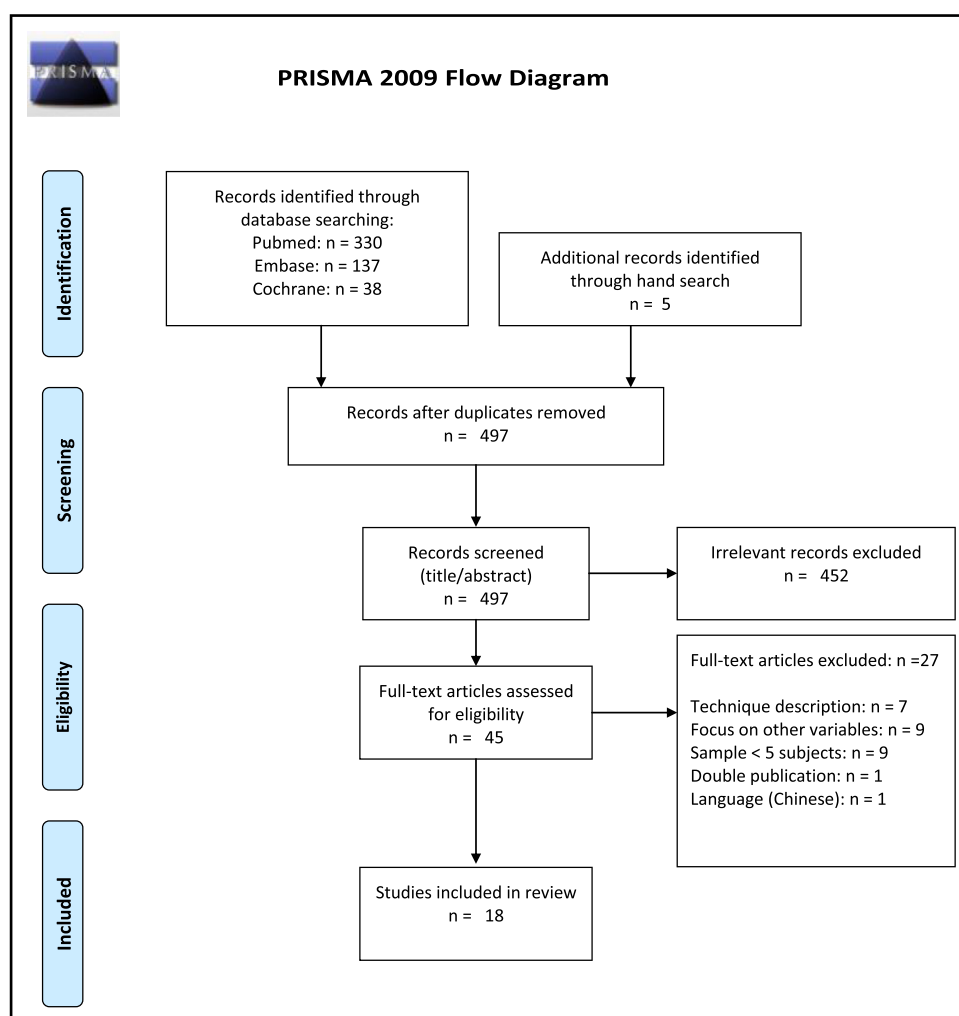
**Fig 1.** Different surgical techniques: **A**, periodontally accelerated osteogenic orthodontics or Wilkodontics (buccal and palatal views): mucoperiosteal flaps are raised (*red incision line*); circumscribing decortication was carried out on the palatal or buccal side (*black lines*), followed by bone augmentation (*white dots*). **B**, Corticotomy modification 1: monocortical piezosurgery—mucoperiosteal flap (*red incision line*), cuts with ultrasonic bone saw (*black lines*); “Y”-shaped cuts in interdental crest area to preserve crestal bone. **C**, Corticotomy modification 2: monocortical perforations (*black dots*) in areas of intended tooth movement; *red line*, incision for flap. **D**, Corticotomy modification 3: piezocision—small vertical incisions (*red lines*) and vertical cuts (*black lines*); limited bone augmentation (*white dots*) is possible through subperiosteal tunneling and injection of graft paste. **E**, PDL distraction (buccal and occlusal views); the first premolars are extracted, and the interseptal bone distal to the canines is undermined by 3 surgical cuts to weaken resistance to distal movement; no flaps are raised; banded jackscrew distractors are placed, and retraction is immediately started at a rate of 0.5-1.0 mm per day. **F**, Dentoalveolar distraction: a buccal flap is raised, and cuts outlining the canine root are made on the buccal cortex (*black lines*); the first premolar and the buccal cortical plate lining the extraction socket are removed; the cut mesial to the canine is extended to the lingual/palatal cortex; the lingual/palatal cortex and the trabecular bone apical to the canine are left intact; the alveolar segment containing the canine is retracted with banded jackscrew distractors at a rate of 0.5-1.0 mm per day.

their widespread acceptance among orthodontists and patients. Therefore, more conservative flapless corticotomy techniques have recently been proposed.<sup>3,4</sup> These procedures can be completed more quickly and might be preferable if patient discomfort is indeed minimized, and if treatment efficiency is maintained. Corticotomy-facilitated orthodontics has been indicated for nonextraction treatment of crowding,<sup>7</sup> shortening treatment duration,<sup>4,8</sup> borderline orthognathic surgery patients,<sup>8,9</sup> extrusion of ankylosed teeth,<sup>9</sup> intrusion of posterior teeth to close anterior open bites,<sup>10</sup> faster canine retraction in extraction patients,<sup>11</sup> and impacted canines.<sup>12</sup>

Another group of techniques is based on distraction principles. In periodontal ligament (PDL) distraction<sup>13</sup> and dentoalveolar distraction,<sup>14,15</sup> bony resistance is surgically reduced to facilitate rapid canine retraction in premolar extraction patients, with minimal posterior anchorage loss. Proposed indications were Class II Division 1 malocclusion, (bimaxillary) protrusion, and anterior crowding. [Figure 1](#) shows and explains different corticotomy and distraction protocols.

Corticotomy is not a new concept; it was first mentioned at the end of the 19th century. Although various techniques have been reported to be successful in practice, scientific substantiation for their effectiveness and safety so far has been limited to case series and a handful of clinical trials, generally with small groups. Critical analysis and comparison of the data of these studies might provide more reliable results and lead to refinement of the protocols. Therefore, a systematic review of the literature was indicated. The aim of this study was to find answers to the following questions.

1. Does surgically facilitated orthodontic treatment significantly increase the velocity of tooth movement and shorten treatment duration in healthy orthodontic patients, compared with conventional orthodontics?
2. Is there a difference in the incidence of tooth vitality loss, periodontal problems, and root resorption between healthy orthodontic patients treated with



**Fig 2.** Flowchart of the literature selection process.

surgically facilitated orthodontics and patients who had orthodontic treatment without surgery?

- Do the designs of the cortical cuts and the gingival flaps influence the efficiency of tooth movement and the incidence of complications?

## MATERIAL AND METHODS

Articles regarding corticotomy-facilitated orthodontics or dental distraction in healthy adolescent or adult patients without craniofacial anomalies or periodontal disease were considered. Randomized controlled trials (RCT), controlled clinical trials (CCT), and case series (CS) with sample sizes of 5 or more patients were eligible for inclusion in this review. Publications on segmental osteotomies and surgically assisted rapid maxillary expansion were not taken into account. Studies needed to focus on the velocity of tooth movement or treatment

time reduction, tissue health or complications, or comparisons between different surgical techniques to be included. Mere descriptions of techniques or protocols were rejected. Only full-length articles were considered. There were no predetermined restrictions on language, publication year, publication status, initial malocclusion, or indication for treatment.

The PubMed, Embase, and Cochrane databases were searched for literature published until April 2013 using the following keywords in all fields: surg\* assisted tooth movement, rapid tooth movement, corticotomy AND orthodontics, corticotomy-facilitated orthodontics, accelerated tooth movement, (piezosurgery OR piezocision) AND orthodontics, regional accelerated phenomenon AND orthodontics, RAP AND orthodontics, accelerated osteogenic orthodontics. The results were limited to human studies. To complete the search, reference lists of the included studies were manually checked.

The studies were assessed for eligibility and graded by 2 observers (E.J.H. and Y.R.). First, the hits by the search engines were screened for relevance based on title and abstract. Publications that were not related to our topic or clearly did not meet the required research designs were excluded. All relevant publications and all studies with abstracts providing insufficient information to justify a decision on exclusion were obtained in full text. If electronic articles were unavailable, the authors were contacted. The 2 observers applied the inclusion criteria separately. In case of disagreement, a consensus decision was made. Data extraction tables were used to collect and present findings from the included studies. The type of surgical intervention, the number of subjects, the tooth type, internal or external control group, the orthodontic force system used and the frequency of adjustments, the latency between surgery and orthodontic activation, the rate of tooth movement and the reduction in treatment time (if stated), and the incidence of complications (tooth vitality loss, periodontal problems, or root resorption) were extracted.

A 3-point grading system, as described by the Swedish Council on Technology Assessment in Health Care and the Centre for Reviews and Disseminations (York), was used to rate the methodologic quality of the articles (Table I).<sup>16,17</sup> This tool was also used to assess the level of evidence for the conclusions of this review. Furthermore, for RCTs and CCTs (potentially producing moderate-to-strong levels of evidence), the Cochrane Collaboration's tool for assessing risk of bias was used.<sup>18</sup> Case series without controls were not assessed with this tool because the risk of bias is inherently high with such study designs.

## RESULTS

The search results are depicted in a flowchart (Fig 2); 505 studies were identified in the electronic databases, and 5 additional ones were found by hand searching of the reference lists. After exclusion of irrelevant titles and abstracts, 45 full-text articles were assessed for eligibility. One study on PDL retraction published in Chinese was excluded based on language.<sup>19</sup> Application of the inclusion criteria resulted in 19 eligible publications. Two studies appeared to contain overlapping data<sup>15,20</sup>; only the study with a control group was selected.<sup>15</sup> Finally, 18 studies were included in the review.

There was complete interrater consensus on the literature selection process and grading of the publications. The design and grading of the publications are presented in Table II. The data extracted from the studies are presented in Table III. Four RCTs (3 with a split-mouth design) and 3 CCTs could be included. These studies were graded as

**Table I.** Grading system

<i>Grade of publication</i>	<i>Criteria</i>
A: High value of evidence	All criteria should be met: RCT or prospective study with a well-defined control group Defined diagnosis and end points Diagnostic reliability tests and reproducibility tests described Blinded outcome assessment
B: Moderate value of evidence	All criteria should be met: Clinical trial, cohort study, or case series Defined control or reference group Defined diagnosis and end points
C: Low value of evidence	One or more of the following conditions: Lack of a control group Large attrition of the sample Unclear diagnosis and end points Poorly defined patient material
<i>Level of scientific support</i>	<i>Definition</i>
Strong	At least 2 studies with high value of evidence
Moderate	One study with high and at least 2 with moderate value of evidence
Limited	At least 2 studies with moderate value of evidence
Inconclusive	Fewer than 2 studies with moderate value of evidence

having a moderate value of evidence (B) because reliability and reproducibility of the diagnostic tools were not described, and outcome assessment was not blinded in 6 of the 7. All other studies were case series without a control group and were therefore graded as having a low value of evidence (C). All clinical trials were judged to have certain risks of bias, as specified in Table IV. The combined number of patients treated with surgically facilitated orthodontics in the included studies was 286 (distraction procedures,  $n = 203$ ; corticotomy procedures,  $n = 83$ ). In only 1 article, bone augmentation was incorporated in the corticotomy procedure ( $n = 10$ ).<sup>21</sup>

In general, orthodontic appliances were placed before surgery, activated immediately or shortly after surgery, and adjusted at short intervals (at least every 2 weeks with corticotomy, once or twice daily with distraction) to optimally take advantage of the temporarily (3-4 months) increased bone turnover. The amount of tooth movement was directly compared with a control group in 2 studies on corticotomy.<sup>11,12</sup> Shortly after surgery, the rate of tooth movement was doubled; after 3 months, the acceleratory effect ceased.<sup>11</sup> In both studies, the measurements were made on dental casts; Aboul-Ela et al<sup>11</sup> used the palatal rugae as a reference to measure canine retraction. Fischer<sup>12</sup> measured the linear distance

**Table II.** Design and grading of included studies

<i>Study</i>	<i>Design</i>	<i>Defined diagnosis and endpoints</i>	<i>Diagnostic reliability/reproducibility tests described</i>	<i>Blind</i>	<i>Grade</i>	<i>Duration of experiment/follow-up</i>
Shoreiba et al <sup>21</sup> 2012	RCT	Yes; mean grey value of alveolar bone, measured on periapical x-rays with special software, was used to quantify bone density. Root length measured on periapical x-rays from cementoamel junction to apex to assess root resorption. Periodontal health assessed by probing depth. Data recorded at pretreatment, at debracketing, and 6 months into retention. End point: finished orthodontic treatment.	No	No	B	3.5-5 months treatment duration/6 months retention
Mowafy and Zaher <sup>28</sup> 2012	RCT, split mouth	Yes; displacement of canines and first molars related to palatal rugae, digitally measured (twice) on scanned images of the plaster models. Tipping of teeth measured on panoramic x-rays, using a horizontal line through the orbital fossae as reference. End point: full canine retraction.	Partially	No	B	1-11 months canine retraction/not specified
Aboul-Ela et al <sup>11</sup> 2011	RCT, split mouth	Yes; periodontal health assessed by plaque index, gingival index, probing depth, attachment level, and gingival recession pretreatment, and after 4 months of canine retraction. Tooth displacement measured monthly on plaster models. End point: 4 months of canine retraction.	No	No	B	4 months of canine retraction/not specified
Fischer <sup>12</sup> 2007	RCT, split mouth	Yes; distance from tip of impacted canine to its final position in the arch was measured on plaster casts 2 weeks after surgical exposure. Time required to bring the canine tip to its correct position was recorded (in weeks), and velocity of tooth movement was calculated. Periodontal health was assessed by probing once canines were in their final resting positions. Periapical x-rays taken 1 year posttreatment to compare bone levels. End points: tips of both canines in proper position, 12 months of retention.	No	Yes, single	B	10-20 months to align canines/12 months retention

Table II. Continued

Study	Design	Defined diagnosis and endpoints	Diagnostic reliability/reproducibility tests described	Blind	Grade	Duration of experiment/follow-up
Shoreiba et al <sup>22</sup> 2012	CCT	Yes; mean grey value of alveolar bone, measured on periapical x-rays using special software, was used to quantify bone density. Root length measured on periapical x-rays from cementoamel junction to apex to assess root resorption. Periodontal health assessed by probing depth. Data recorded at pretreatment, at debracketing, and 6 months into retention. End point: finished orthodontic treatment.	No	No	B	4-12 months treatment duration/6 months retention
Kharkar et al <sup>15</sup> 2010	CCT, split mouth	Yes; root resorption assessed on periapical x-rays after 6 days, full canine retraction, 1, 3, and 6 months. Displacement and tipping of canines and molars measured on lateral cephalograms after canine retraction and after 3 months. Electric pulp test pretreatment, after removal of distractors, 6 and 12 months. End points: end of canine retraction, 3, 6, and 12 months after distraction.	No	No	B	2-3 weeks canine retraction/12 months after distraction
Gantes et al <sup>23</sup> 1990	CCT	Yes; periodontal health assessed by plaque scores, probing depth, probing attachment level (electronic probe, measured to the nearest 0.5 mm). Measurements for vitality/root resorption unclear or not stated. End point: finished orthodontic treatment.	No	No	B	15-28 months treatment duration/not specified
Hernandez-Alfaro and Guijarro-Martinez <sup>2</sup> 2012	CS	Unclear: pulp vitality and probing depth evaluated at least once per month. Bone levels and root resorption assessed radiographically during 12-month follow-up. Methods not stated. End points unclear.	No	No	C	Unclear/12 months
Kisnisci and Iseri <sup>24</sup> 2011	CS	Yes; root resorption assessed on periapical and panoramic x-rays using scale (4 categories). Thermal and electric pulp tests. Timing of data collection not clearly stated. End points unclear, retrospective case selection.	No	No	C	1-2 weeks distraction/6 months after distraction

Table II. Continued

<i>Study</i>	<i>Design</i>	<i>Defined diagnosis and endpoints</i>	<i>Diagnostic reliability/reproducibility tests described</i>	<i>Blind</i>	<i>Grade</i>	<i>Duration of experiment/follow-up</i>
Bertossi et al <sup>9</sup> 2011	CS	Unclear diagnosis and methods. Postoperative follow-up examinations at 3, 4, 7, and 30 days, and then every 2 weeks for 2 months. Pain, edema, and pocket depth assessed. Tooth sensitivity evaluated by thermal test (ice). End point: finished orthodontic treatment.	No	No	C	1-5 months treatment duration/not specified
Akay et al <sup>10</sup> 2009	CS	Intrusion of premolars and molars measured on lateral cephalograms. Root resorption assessed on panoramic x-rays, but method unclear. End points not clearly stated (intrusion took 12-15 weeks).	No	No	C	12-15 weeks intrusion, total treatment duration unclear/not specified
Kumar et al <sup>29</sup> 2009	CS	Yes; displacement and tipping of canines and molars measured on lateral cephalograms and panoramic x-rays before and after complete canine retraction. Apical and lateral root resorption assessed on periapical x-rays directly, 1 and 6 months after canine retraction using scale (4 categories). Electric pulp test immediately after distraction, and after 1 and 6 months. End points: complete canine retraction, 6 months after distraction.	No	No	C	3 weeks canine retraction/6 months after distraction
Sukurica et al <sup>25</sup> 2007	CS	Yes; displacement of canines and molars measured on predistracted and postdistracted plaster models using a reference grid. Tipping of canines and molars measured on panoramic x-rays using reference lines. Periodontal health assessed by probing depth (3 sites per tooth), vitality checked with electric pulp tests, and root resorption evaluated on periapical x-rays predistracted and postdistracted, and 6 months after distraction. End points: end of distraction phase, 6 months after distraction.	No	No	C	2-4 weeks canine retraction/6 months after distraction
Gürgeç et al <sup>26</sup> 2005	CS	Yes; periodontal health evaluated by plaque index, gingival index, pocket depth (4 sites per tooth), and width of keratinized gingiva pretreatment, directly and 1, 6, and 12 months postdistracted. Assessment of vitality and root resorption unclear. End points: 1, 6, and 12 months after canine distraction.	No	No	C	1-2 weeks canine retraction/12 months after distraction

Table II. Continued

Study	Design	Defined diagnosis and endpoints	Diagnostic reliability/reproducibility tests described	Blind	Grade	Duration of experiment/follow-up
Iseri et al <sup>27</sup> 2005	CS	Yes; root resorption assessed on periapical and panoramic x-rays using scale (4 categories) predistracted and postdistracted. Vitality checked by electric pulp test. Displacement and tipping of canines and molars measured on lateral cephalograms. End point: end of canine distraction phase.	Partially	No	C	1-2 weeks canine retraction/not specified
Sayin et al <sup>30</sup> 2004	CS	Yes; root resorption and bone levels were assessed on periapical x-rays pretreatment and weekly during distraction. Tooth displacement measured (caliper) intraorally, on plaster models and lateral cephalograms predistracted and postdistracted. Measurement of periodontal parameters unclear. End point: end of canine distraction phase.	No	No	C	3 weeks canine retraction/unclear
Kisnisci et al <sup>14</sup> 2002	CS	Unclear diagnosis and end points; root resorption evaluated on periapical and panoramic x-rays, vitality tests not specified.	No	No	C	1-2 weeks canine retraction/4-11 months after distraction
Liou and Huang <sup>13</sup> 1998	CS	Yes; distance between canine and lateral incisor recorded intraorally with caliper every week until canine retraction was completed. Anchorage loss (molar) measured on lateral cephalograms predistracted and postdistracted. Apical and lateral root resorption assessed on periapical x-rays predistracted and postdistracted using scale (4 categories). Vitality checked with electric pulp test before and at least 1 month after distraction. End point: 3 months after canine distraction phase.	No	No	C	3 weeks canine retraction/3 months after distraction

of the palatally exposed canine tips to their planned position in the arch when orthodontic traction was started (2 weeks after surgery). The mean velocity of tooth movement was calculated once the canine crowns reached their proper position. Two other studies compared treatment duration in the corticotomy group with a control group, matched by the amount of crowding<sup>22</sup> or the malocclusion.<sup>23</sup> In the first study, the average time needed to finish treatment was reduced to 17.5 weeks, compared with 49 weeks in the control group.<sup>22</sup> In the second study, the average treatment duration was reduced to 14.8 months, compared with 28.3 months

in the control group.<sup>23</sup> However, the treatment goals were not specified, and both studies lacked outcome assessments. In general, the reported reductions in total treatment time ranged from 30%<sup>12</sup> to 70%<sup>22</sup> among the publications on corticotomy (Table III).

In the premolar extraction patients, canine retraction was fully accomplished within 2 weeks with dentoalveolar distraction<sup>14,15,24-27</sup> and within 3 to 5 weeks with PDL distraction.<sup>13,15,28-30</sup> One study on PDLs showed that tooth movement was only significantly enhanced if a jackscrew type of appliance was used; the coil spring used in the control group resulted in much



slower, but more bodily retraction.<sup>28</sup> Distal tipping of the canines averaged 10° to 15° with the distraction protocols and obviously needed correction in the next phase of treatment with fixed appliances. Sayin et al<sup>30</sup> estimated that the reduction in total treatment duration was 3 to 4 months with PDL distraction. Studies on dentoalveolar distraction reported 6 to 9 months<sup>26</sup> or even a 50% reduction in overall treatment duration.<sup>24,27</sup> However, no control groups were used in these studies, leaving it unclear what these calculations were based on.

All publications claimed enhanced tooth movement after surgery, but only 4 studies (all of moderate value of evidence, grade B) used a control group having conventional orthodontic treatment.<sup>11,12,22,23</sup> Therefore, there is only a limited level of evidence supporting that surgically facilitated orthodontic treatment significantly reduces treatment duration compared with conventional orthodontic treatment.

As for complications, no clinical signs of tooth vitality loss were reported in any studies. Three studies on corticotomy-facilitated orthodontics stated that “all teeth remained vital,” but the diagnostic tools were not specified, nor were data provided.<sup>4,9,23</sup> No changes in tooth sensibility were detected in 5 of the studies on dental distraction. Only 3 of these mentioned the diagnostic tool (electronic or thermal pulp test).<sup>15,24,29</sup> However, in 3 other studies, several canines did not show a positive response to electronic pulp tests.<sup>13,25,27</sup> The validity of this test during active orthodontic treatment was questioned because untreated neighboring teeth also tested negative in some patients.<sup>13</sup> Based on these findings, the evidence regarding tooth vitality after surgically facilitated orthodontics is inconclusive.

Periodontal problems were assessed in 4 studies on distraction and in 7 studies on corticotomy-facilitated orthodontics; these studies comprised various surgical protocols with different incisions and flaps. In general, none of them resulted in detrimental effects (increased probing depth, recession, attachment loss, or bleeding on probing) on the periodontium, compared with baseline values or a control group. A small mean decrease in pocket depth after treatment (0.2–1.5 mm) was recorded in some publications.<sup>21–23</sup> Five grade B and 2 grade C studies provide limited levels of evidence that surgically facilitated orthodontic treatment is safe for the periodontal tissues.

Root resorption was assessed in all studies on distraction and in 5 studies on corticotomy. None reported significant root shortening when compared with the control group or the pretreatment root length. In some studies, even less root resorption was observed in the corticotomy group than in the controls.<sup>21</sup> Again, limited evidence supports that root resorption after surgically

facilitated orthodontics does not exceed the resorption observed with conventional orthodontic treatment.

We considered the effect of the surgical protocol on the efficiency of tooth movement and complications. One study compared corticotomy with bone augmentation with corticotomy alone. Treatment duration was not influenced by the augmentation, but posttreatment bone density was significantly enhanced.<sup>21</sup> Another study showed that dentoalveolar distraction facilitated slightly faster canine retraction, with less tipping than the more conservative PDL distraction.<sup>15</sup> In the dentoalveolar distraction group, no root resorption was observed, and in the PDL distraction group, 1 canine had minimal root resorption. No complications that would significantly favor one technique over the other were reported in these studies.

## DISCUSSION

To our knowledge, this is the first systematic review on surgically facilitated orthodontic treatment. The heterogeneity of clinical indications, treatment plans, surgical techniques, and force systems did not permit a meta-analysis, and it complicated the interpretation of the results. Most of the included studies had small samples. The scientific quality of these publications was moderate or low, resulting in several risks of bias. The outcomes would have been more valuable if diagnostic reliability and reproducibility tests had been described, and if measurements were blind when applicable (eg, using plaster models or x-rays). A decision was made to consider uncontrolled case series as well. Although these studies could contribute only to the lowest level of scientific evidence, they can still provide valuable clinical information. The outcome of the studies was consistent: both corticotomy-facilitated orthodontics and distraction temporarily enhanced tooth displacement, with minimal complications. This consistency might contribute to the reliability of the findings, but potential publication bias also should be acknowledged. After dental distraction, tooth vitality could not be reliably confirmed in some studies.<sup>13,24,27</sup> However, no discoloration, pain, or radiographic evidence of vitality loss was observed.<sup>13,15,24–27,29</sup> The validity of pulp tests during active treatment was questioned, and the use of a laser Doppler flow meter was suggested for future research.<sup>13,29</sup> Prospective studies with longer observation periods should clarify whether there are any risks to the dental pulp.

Root resorption was minimal after surgically facilitated treatment, although the applied forces were generally higher than with conventional treatment. Histologic research on premolars extracted after arch expansion

**Table III.** Extracted data of included studies

<i>Publications on surgically facilitated dental distraction procedures</i>					
<i>Author/year</i>	<i>Intervention</i>	<i>#S</i>	<i>Tooth type</i>	<i>C</i>	<i>Force (cN)</i>
Mowafy and Zaher <sup>28</sup> 2012	Periodontal ligament distraction	30	U3	1	JS
	Canine retraction with nickel-titanium coil	30	U3	1	CS (½ of JS force)
Kisnisci and Iseri <sup>24</sup> 2011	Dentoalveolar distraction	73	U3	0	JS
Kharkar et al <sup>15</sup> 2010	Dentoalveolar distraction	6	U3	1	JS
	Periodontal ligament distraction	6	U3	1	JS
Kumar et al <sup>29</sup> 2009	Periodontal ligament distraction	8	U3	0	JS
Sukurica et al <sup>25</sup> 2007	Dentoalveolar distraction	8	U3, L3	0	JS
Gürkan et al <sup>26</sup> 2005	Dentoalveolar distraction	18	U3	0	JS
Iseri et al <sup>27</sup> 2005	Dentoalveolar distraction	10	U3	0	JS
Sayin et al <sup>30</sup> 2004	Periodontal ligament distraction	18	U3, L3	0	JS
Kisnisci et al <sup>14</sup> 2002	Dentoalveolar distraction	11	U3, L3	0	JS
Liou and Huang <sup>13</sup> 1998	Periodontal ligament distraction	15	U3, L3	0	JS
<i>Publications on corticotomy-facilitated orthodontics</i>					
Shoreiba et al <sup>22</sup> 2012	Buccal vertical interradicular corticotomies	10	L1-L3	2	FA
	Orthodontic treatment only	10		2	FA
Shoreiba et al <sup>21</sup> 2012	Buccal vertical interradicular corticotomies	10	L1-L3	2	FA
	Buccal interradicular corticotomies + bone augmentation	10	L1-L3	2	FA
Hernandez-Alfaro and Guijarro-Martinez <sup>2</sup> 2012	3 buccal vertical interradicular corticotomies per arch with tunnel approach/piezosurgery	9	Full arches	0	FA
Aboul-Ela et al <sup>11</sup> 2011	Buccal corticotomies (perforations) in the U2-U4 region and extraction of U4	13	U3	1	CS 150 (+FA)
	Extraction U4 + conventional orthodontics	13	U3	1	CS 150 (+FA)
Bertossi et al <sup>9</sup> 2011	Buccal interradicular + subapical corticotomies to extrude ankylosed teeth or accommodate arch expansion	10	Various	0	FA
Akay et al <sup>10</sup> 2009	Buccal and palatal vertical + subapical corticotomies to facilitate intrusion of posterior teeth to close anterior open bite	10	U4-7	0	CS 200-300/molar 100-150/premolar + FA (segmented)
Fischer <sup>12</sup> 2007	Canine exposure + multiple cortical perforations at canine level	6	U3	1	FA, 60
	Conventional canine exposure	6	U3	1	FA, 60
Gantes et al <sup>23</sup> 1990	Buccal + lingual interradicular + subapical corticotomies	5	Full arches	2	FA
	Orthodontic treatment only	4	Full arches	2	FA

*#S*, Number of subjects; *U*, upper arch; *L*, lower arch; *1-2*, incisors; *3*, canine; *4-5*, premolars; *6-7*, molars; *C*, control group; *0*, no control; *1*, split-mouth design; *2*, parallel arms; *Reduct*, reduction in treatment time compared with conventional orthodontic treatment; *Vit loss/Perio/RR*, tooth vitality loss, periodontal problems, or root resorption; *?*, not investigated; *NS*, not significantly different from control group or baseline value; *JS*, jackscrew; *CS*, coil spring; *FA*, fixed appliances; *d*, days; *w*, weeks; *mo*, months; *AL*, less than 1 mm anchorage loss; *\**, canine retraction estimated at 6 mm if not exactly stated (full canine retraction); *-*, not specified.

showed less hyalinization and root resorption on the pressure side in the corticotomy group than in the controls.<sup>31-33</sup> This suggests that elimination of cortical resistance or increased local tissue metabolism might prevent excessive pressure buildup in the PDL and subsequent hyalinization.

To improve patient perception and lessen discomfort, minimally invasive corticotomy techniques have

been proposed.<sup>3,4</sup> However, no studies of pain, tissue swelling, and other complications with different flaps or corticotomy designs were found. One study compared “oral health-related quality of life” after corticotomy with piezoelectric vs rotary instruments. Similar occasional discomfort was reported, but only during the first week after surgery.<sup>34</sup> In other studies, patients reported less discomfort than they had

**Table III.** Continued

<i>Publications on surgically facilitated dental distraction procedures</i>				
<i>Latency</i>	<i>Activation</i>	<i>Rate of tooth movement</i>	<i>Reduct</i>	<i>Vit loss/Perio/RR</i>
0 d	1 turn/d	5.9 ± 1.4 mm retraction in 37 ± 10 d, 10° tipping, 2.5 ± 0.9 mm AL	–	?/??
0 d	Continuous	4.7 ± 1.6 mm retraction in 195 ± 47 d, 0.3° tip, 2.8 ± 1.5 mm AL	–	?/??
1-2 d	0.8 mm/d	±5 mm retraction* in 10 d (9-14 d)	50%	No/no/no
2 d	0.5 mm/d	±5 mm retraction* in 12.5 d; 10° tipping, minimal AL	–	No/?/no
0 d	0.5 mm/d	±5 mm retraction* in 19.5 d, 15° tipping, minimal AL	–	No/?/1 canine minimal RR
0 d	0.5 mm/d	5.2 mm retraction in 20 d; 15° tipping, minimal AL	–	No/?/NS
3 d	0.5 mm/d	5.4 ± 1.2 mm retraction in 14.7 ± 3.5 d, 9° tipping, 1.2 ± 0.8 mm AL	–	13 canines no pulpal response/NS/NS
1-3 d	0.8 mm/d	±5 mm retraction* in 10.4 d (8-14 d), no AL	6-9 mo/ 50%	No/no/no
1-3 d	0.8 mm/d	±5 mm retraction* in 10.0 d (8-14 d), 13° tipping, minimal AL	50%	All canines: no pulpal response/?/no
0 d	0.75 mm/d	5.8 mm retraction in 21 d, 12° tipping, minimal AL	3-4 mo	?/no/NS
0 d	0.8 mm/d	±5 mm retraction* in 8-14 d	–	No/?/no
0 d	0.5-1.0 mm/d	6.5 mm retraction in 21 d, minimal tipping and AL	–	17 canines no pulpal response/?/no
0 d	once/2 w	Mean treatment duration 17.5 w	66%	?/NS/less RR
	–	Mean treatment duration 49 w		
0 d	once/2 w	Mean treatment duration 17 w (14-20)	–	?/NS/NS
0 d	once/2 w	Mean treatment duration 16.7 w (14-20)	–	?/NS/NS
				26% increased bone density
1 d	–	–	–	No/no/no
0 d	–	1.9 mm in 30 d, 3.7 mm in 60 d, 4.8 mm in 90 d, 5.7 mm in 120 d	–	?/NS/?
0 d	–	0.8 mm in 30 d, 1.6 mm in 60 d, 2.5 mm in 90 d, 3.4 mm in 120 d		
1-7 d	–	4-5 mm extrusion of ankylosed premolars in 18-25 d; 6-8 mm maxillary expansion in 68-150 d	65%-70%	No/no/?
7 d	once/3 w	3-3.5 mm intrusion in 84-105 d	–	?/?/NS
2 w	once/2-6 w	10-14 mm canine movement in 266-378 d, mean 0.3 mm/w	28%-33%	?/NS/?
2 w	once/2-6 w	11-15 mm canine movement in 406-546 d, mean 0.2 mm/w		
0 d	–	Mean treatment time 14.8 mo (11-20 mo)	50%	No/NS/NS
	–	Mean treatment time 28.3 mo (24-35 mo)		

expected<sup>23</sup> and showed better motivation.<sup>22</sup> With PDL distraction, patients did not report pain, other than the usual tenderness of the teeth during orthodontic treatment.<sup>28</sup>

Expansion of crowded arches might compromise vestibular bone thickness and result in root dehiscences or fenestrations. It has been claimed that this problem could be avoided with corticotomy-facilitated

orthodontics and bone augmentation,<sup>6,35</sup> decreasing the need for extraction treatment.<sup>7</sup> Only 1 study compared changes in bone volume after corticotomy with and without bone augmentation.<sup>21</sup> In both groups, bone density decreased during treatment. Six months into retention, bone density was restored in the corticotomy group and had increased by 26% in the bone-graft group. Another study used corticotomy with bone

**Table IV.** Risk of bias in clinical trials

Publication	Selection bias						
	Random	Allocation	Performance	Detection	Attrition	Reporting	Other
Shoreiba et al <sup>21</sup> 2012	?	?	?	Low	High, 3 dropouts	?	?
Mowafy and Zaher <sup>28</sup> 2012	Low	?	Low	High	Low	Low	?
Aboul-Ela et al <sup>11</sup> 2011	Low (coin toss)	?	Low	?	Low (split-mouth design), 2 dropouts	?	?
Fischer <sup>12</sup> 2007	?	?	Low	Low	Low	?	?
Shoreiba et al <sup>22</sup> 2012	?	?	High	High	Low	?	?
Kharkar et al <sup>15</sup> 2010	High	?	?	High	Low	High	?
Gantes et al <sup>23</sup> 1990	High	High	High	High	Low	Low	?

*Random*, Random sequence generation; *Allocation*, allocation concealment; *Performance*, performance bias, blinding of participants and personnel; *Detection*, detection bias, blinding of outcome assessment; *Attrition*, attrition bias, incomplete outcome data; *Reporting*, reporting bias, selective reporting; ?, unclear risk of bias.

augmentation to facilitate proclination of the mandibular incisors in the presurgical decompensation of Class III patients. The mean labial bone thickness had increased by 1.6 to 2.0 mm at the end of the presurgical phase, and no gingival recession was observed.<sup>36</sup> So far, published data on long-term maintenance of bone volume after augmentation are scarce. Enhanced alveolar thickness and successful covering of preexisting fenestrations have been demonstrated in a number of cases with computed tomography scans and bone biopsy (2-11 years after treatment).<sup>6,7,35</sup>

Clinical experience has led to the claim that relapse after corticotomy-facilitated treatment is minimal because of increased root support after healing and loss of "tissue memory" by the high turnover and remodeling processes.<sup>2,5-7,35</sup> No clinical trials properly addressing long-term stability could be included in this review. A few abstracts were found reporting on better American Board of Orthodontics scores and a more stable transverse dimension in the corticotomy group.<sup>37,38</sup>

The mechanism underlying accelerated tooth movement has been the subject of discussion. Initially, it was believed that a corticotomy facilitated segmental movement of alveolar blocks by means of tooth-borne distraction.<sup>5</sup> If resistance is sufficiently eliminated, this concept might apply: in experiments with rats, if molars were protracted after a partial osteotomy, bone remodeling was exclusively noted in the distraction gap; the bone between the roots remained unaffected. However, marked bone demineralization around the roots was observed when a corticotomy without segment mobilization was carried out.<sup>39</sup> The rapid tooth movement after a corticotomy has often been attributed to a local increase in metabolism and transient osteopenia (regional accelerated phenomenon), rather than "bony block movement."<sup>40-42</sup> Temporary loss of bone mass after the corticotomy has indeed been demonstrated in humans by means of x-rays and cone-beam computed tomography.

Postretention remineralization was noted.<sup>7,21</sup> Similar findings have been reported in rat experiments.<sup>39,43,44</sup> The expression of several inflammatory cytokines and receptors was doubled or tripled after corticotomy.<sup>45</sup> Tracing markers for osteoclast regulation and osteoblastic activity showed a coupled increase in catabolic and anabolic activity after corticotomy. Immediate continuous tooth movement without a lag phase was observed, in contrast to the "classical" tooth movement in the control group. Four to 6 weeks after surgery, bone homeostasis was restored, and bone mineral volume and mass appeared to exceed baseline values in the corticotomy group.<sup>46</sup> The velocity of tooth movement had returned to normal after the healing phase.

Clinical observations and well-designed animal experiments have clearly shown temporarily accelerated tooth movement after alveolar surgery. However, it is less clear how this affects the overall treatment duration, since this would depend on the indication, the correct timing of surgery, and the skill of the clinician. Moreover, the number of appointments and the amount of chair time needed to finish treatment might not decrease because of the recommended shorter intervals between checkups. Therefore, it is difficult to determine whether any reduction in treatment duration would outweigh the extra cost of the surgical procedure. Prospective trials, with proper methodology and larger samples, are still needed and should focus on comparing different surgical approaches on efficiency, complications, patient perceptions, and long-term stability. Furthermore, the potential of surgically facilitated orthodontics to treat clinical problems such as ankylosed teeth<sup>9</sup> or closure of alveolar defects<sup>26</sup> might be further explored soon.

## CONCLUSIONS

Surgically facilitated orthodontics is characterized by a temporary phase of accelerated tooth movement; this

might effectively shorten the duration of treatment, but careful treatment planning, early activation of appliances, and short intervals between checkups are recommended. Surgically facilitated orthodontics is not associated with complications such as loss of tooth vitality, periodontal problems, or severe root resorption. However, the level of evidence is limited owing to shortcomings in methodologies and the small numbers of patients in the studies. Due to a lack of comparative data, it is unclear which surgical protocol is preferable regarding treatment efficiency and safety. Well-conducted, prospective research is still needed to draw valid conclusions.

## REFERENCES

- Dibart S, Sebaoun JD, Surmenian J. Piezocision: a minimally invasive, periodontally accelerated orthodontic tooth movement procedure. *Compend Contin Educ Dent* 2009;30:342-4:346, 348-50.
- Hernandez-Alfaro F, Guijarro-Martinez R. Endoscopically assisted tunnel approach for minimally invasive corticotomies: a preliminary report. *J Periodontol* 2012;83:574-80.
- Roblee RD, Bolding SL, Landers JM. Surgically facilitated orthodontic therapy: a new tool for optimal interdisciplinary results. *Compend Contin Educ Dent* 2009;30:264-75.
- Suya H. Corticotomy in orthodontics. In: Hosl E, Baldauf A, editors. *Mechanical and biological basics in orthodontic therapy*. Heidelberg, Germany: Huthig Buch Verlag; 1991. p. 207-26.
- Köle H. Surgical operations on the alveolar ridge to correct occlusal abnormalities. *Oral Surg Oral Med Oral Pathol* 1959;12:515-29.
- Wilcko WM, Wilcko MT, Bouquot JE, Ferguson DJ. Rapid orthodontics with alveolar reshaping: two case reports of decrowding. *Int J Periodontics Restorative Dent* 2001;21:9-19.
- Wilcko MT, Wilcko WM, Bissada NF. An evidence-based analysis of periodontally accelerated orthodontic and osteogenic techniques: a synthesis of scientific perspectives. *Semin Orthod* 2008;14:305-16.
- Vercellotti T, Podesta A. Orthodontic microsurgery: a new surgically guided technique for dental movement. *Int J Periodontics Restorative Dent* 2007;27:325-31.
- Bertossi D, Vercellotti T, Podesta A, Nocini PF. Orthodontic microsurgery for rapid dental repositioning in dental malpositions. *J Oral Maxillofac Surg* 2011;69:747-53.
- Akay MC, Aras A, Gunbay T, Akyalcin S, Koyuncue BO. Enhanced effect of combined treatment with corticotomy and skeletal anchorage in open bite correction. *J Oral Maxillofac Surg* 2009;67:563-9.
- Aboul-Ela SM, El-Beialy AR, El-Sayed KM, Selim EM, El-Mangoury NH, Mostafa YA. Miniscrew implant-supported maxillary canine retraction with and without corticotomy-facilitated orthodontics. *Am J Orthod Dentofacial Orthop* 2011;139:252-9.
- Fischer TJ. Orthodontic treatment acceleration with corticotomy-assisted exposure of palatally impacted canines. *Angle Orthod* 2007;77:417-20.
- Liou EJ, Huang CS. Rapid canine retraction through distraction of the periodontal ligament. *Am J Orthod Dentofacial Orthop* 1998;114:372-82.
- Kisnisci RS, Iseri H, Tuz HH, Altug AT. Dentoalveolar distraction osteogenesis for rapid orthodontic canine retraction. *J Oral Maxillofac Surg* 2002;60:389-94.
- Kharkar VR, Kotrashetti SM, Kulkarni P. Comparative evaluation of dento-alveolar distraction and periodontal distraction assisted rapid retraction of the maxillary canine: a pilot study. *Int J Oral Maxillofac Surg* 2010;39:1074-9.
- Bondemark L, Holm A, Hansen K, Axelsson S, Mohlin B, Brattstrom V, et al. Long-term stability of orthodontic treatment and patient satisfaction. A systematic review. *Angle Orthod* 2007;77:181-91.
- Centre for Reviews and Dissemination. *Systematic Reviews. CRD's guidance for undertaking reviews in health care*. 3rd ed. York, United Kingdom: CRD: University of York; 2009.
- Higgins JPT, Altman DG, Sterne JAC. Assessing risk of bias in included studies. In: Higgins JPT, Green S, editors. *Cochrane handbook for systematic reviews of interventions*. Version 5.1.0; updated March 2011. The Cochrane Collaboration; 2011. Available at: [www.cochrane-handbook.org](http://www.cochrane-handbook.org). Accessed February 2014.
- Ma WS, Dong FS, Ren GY, Feng LX, Hou Y. Rapid canine distalization through distraction of the periodontal ligament after reducing interseptal bone resistance. *Zhonghua Kou Qiang Yi Xue Za Zhi* 2008;43:546-50.
- Kharkar VR, Kotrashetti SM. Transport dentoalveolar distraction osteogenesis-assisted rapid orthodontic canine retraction. *Oral Surg Oral Med Oral Pathol Oral Radiol Endod* 2010;109:687-93.
- Shoreiba EA, Ibrahim SA, Attia MS, Diab MM. Clinical and radiographic evaluation of bone grafting in corticotomy-facilitated orthodontics in adults. *J Int Acad Periodontol* 2012;14:105-13.
- Shoreiba EA, Salama AE, Attia MS, Abu-Seida SM. Corticotomy-facilitated orthodontics in adults using a further modified technique. *J Int Acad Periodontol* 2012;14:97-104.
- Gantes B, Rathbun E, Anholm M. Effects on the periodontium following corticotomy-facilitated orthodontics. Case reports. *J Periodontol* 1990;61:234-8.
- Kisnisci RS, Iseri H. Dentoalveolar transport osteodistraction and canine distalization. *J Oral Maxillofac Surg* 2011;69:763-70.
- Sukurica Y, Karaman A, Gurel HG, Dolanmaz D. Rapid canine distalization through segmental alveolar distraction osteogenesis. *Angle Orthod* 2007;77:226-36.
- Gurgan CA, Iseri H, Kisnisci R. Alterations in gingival dimensions following rapid canine retraction using dentoalveolar distraction osteogenesis. *Eur J Orthod* 2005;27:324-32.
- Iseri H, Kisnisci R, Bzizi N, Tuz H. Rapid canine retraction and orthodontic treatment with dentoalveolar distraction osteogenesis. *Am J Orthod Dentofacial Orthop* 2005;127:533-41.
- Mowafy MI, Zaher AR. Anchorage loss during canine retraction using intermittent versus continuous force distractions; a split mouth randomized clinical trial. *Prog Orthod* 2012;13:117-25.
- Kumar PS, Saxena R, Patil S, Keluskar KM, Nagaraj K, Kotrashetti SM. Clinical investigation of periodontal ligament distraction osteogenesis for rapid orthodontic canine retraction. *Aust Orthod J* 2009;25:147-52.
- Sayin S, Bengi AO, Gurton AU, Ortakoglu K. Rapid canine distalization using distraction of the periodontal ligament: a preliminary clinical validation of the original technique. *Angle Orthod* 2004;74:304-15.
- Byloff-Clar H. Treatment with active plates with and without corticotomy in late cases (juvenile). Clinical and histologic study. *Stoma (Heidelb)* 1967;20:134-41:contd.
- Byloff-Clar H. Treatment with activator plates with and without corticotomy in late cases (juveniles). A clinical and histological study. *Stoma (Heidelb)* 1967;20:214-25:contd.
- Byloff-Clar H. Treatment of delayed (juvenile) cases using activators with and without corticotomy. Clinical and histologic study. *Stoma (Heidelb)* 1967;20:277-86:concl.

34. Cassetta M, Di Carlo S, Giansanti M, Pompa V, Pompa G, Barbato E. The impact of osteotomy technique for corticotomy-assisted orthodontic treatment (CAOT) on oral health-related quality of life. *Eur Rev Med Pharmacol Sci* 2012;16:1735-40.
35. Wilcko MT, Wilcko WM, Pulver JJ, Bissada NF, Bouqout JE. Accelerated osteogenic orthodontics technique: a 1-stage surgically facilitated rapid orthodontic technique with alveolar augmentation. *J Oral Maxillofac Surg* 2009;67:2149-59.
36. Ahn HW, Lee DY, Park YG, Kim SH, Chung KR, Nelson G. Accelerated decompensation of mandibular incisors in surgical skeletal Class III patients by using augmented corticotomy: a preliminary study. *Am J Orthod Dentofacial Orthop* 2012;142:199-206.
37. Nazarov AD, Ferguson DJ, Wilcko WM, Wilcko MT. Improved retention following corticotomy using ABO objective grading system [abstract 2644]. *J Dent Res* 2004;83.
38. Skountrianos HS, Ferguson DJ, Wilcko WM, Wilcko MT. Maxillary arch decrowding and stability with and without corticotomy-facilitated orthodontics [abstract 2643]. *J Dent Res* 2004;83.
39. Lee W, Karapetyan G, Moats R, Yamashita DD, Moon HB, Ferguson DJ, et al. Corticotomy-/osteotomy-assisted tooth movement microCTs differ. *J Dent Res* 2008;87:861-7.
40. Frost HM. The regional accelerated phenomenon. *Orthop Clin N Am* 1981;12:725-6.
41. Ferguson DJ, Wilcko WM, Wilcko MT. Selective alveolar decortication for rapid surgical-orthodontic resolution of skeletal malocclusion treatment. In: Bell WE, Guerrero C, editors. *Distraction osteogenesis of the facial skeleton*. Hamilton, Ontario, Canada: B. C. Decker; 2006. p. 199-203.
42. Yaffe A, Fine N, Binderman I. Regional accelerated phenomenon in the mandible following mucoperiosteal flap surgery. *J Periodontol* 1994;65:79-83.
43. Sebaoun JD, Kantarci A, Turner JW, Carvalho RS, van Dyke TE, Ferguson DJ. Modeling of trabecular bone and lamina dura following selective alveolar decortication in rats. *J Periodontol* 2008;79:1679-88.
44. Teixeira CC, Khoo E, Tran J, Chartres I, Liu Y, Thant LM, et al. Cytokine expression and accelerated tooth movement. *J Dent Res* 2010;89:1135-41.
45. Iglesias-Linares A, Yanez-Vico RM, Moreno-Fernandez AM, Mendoza-Mendoza A, Solano-Reina E. Corticotomy-assisted orthodontic enhancement by bone morphogenetic protein-2 administration. *J Oral Maxillofac Surg* 2012;70:e124-32.
46. Baloul SS, Gerstenfeld LC, Morgan EF, Carvalho RS, Van Dyke TE, Kantarci A. Mechanism of action and morphologic changes in the alveolar bone in response to selective alveolar decortication-facilitated tooth movement. *Am J Orthod Dentofacial Orthop* 2011;139(Suppl):S83-101.